

## Case Report

# Renal cell carcinoma with solitary toe metastasis

SISTO PERDONÀ,<sup>1</sup> RICCARDO AUTORINO,<sup>1</sup> LUIGI GALLO,<sup>1</sup> MARCO DE SIO,<sup>1</sup> LUIGI MARRA,<sup>1</sup> LUIGI CLAUDIO,<sup>1</sup> CORRADO CARACÒ,<sup>2</sup> RENATO FRANCO,<sup>3</sup> FLAVIO FAZZIOLI<sup>2</sup> AND ANTONIO GALLO<sup>1</sup>

<sup>1</sup>Department of Urology, <sup>2</sup>Surgery B and <sup>3</sup>Pathology, National Cancer Institute, I.R.C.C.S. Fondazione 'G. Pascale', Naples, Italy

### Abstract

Solitary metastases to the small bones and/or to the soft tissue of the hands and feet (acrometastases) are rare. We report a case of renal cell carcinoma (RCC) with big toe metastasis revealed before the primary tumor became apparent. The best treatment for a single metastasis is always surgical excision, regardless of the lesion being synchronous or metachronous. The biological behavior of metastatic RCC is unpredictable and only early diagnosis and treatment may favorably affect patient survival. Thus, metastatic RCC should be included in the differential diagnosis of all enlarging cutaneous nodules, wherever they develop.

**Key words** acrometastasis, renal cell carcinoma, synchronous metastasis.

### Introduction

Renal cell carcinoma (RCC) is well known for its unpredictable presentation, mode of spread and tendency to metastasize early. Until recently, approximately a third of cases had metastatic disease at presentation and 50% of those resected for cure were expected to have relapse during the course of the disease.<sup>1</sup> During recent years, with the recent development of imaging techniques, such as ultrasonography, magnetic resonance imaging and computed tomography, and their widespread use, the frequency of small, low stage tumors has grown considerably and the risk of metastatic spread beyond the tumor-bearing kidneys has decreased.<sup>2</sup>

Common metastatic sites for RCC are lung, bone, liver, adrenal gland, brain, abdominal lymph nodes and skin. Solitary metastases to the small bones and/or to the soft tissue of the hands and feet (acrometastases) are rare and may be misdiagnosed as benign or osteoarthritic lesions. Usually acrometastasis is a late manifestation of disseminated disease. In rare cases, it may be the primary manifestation of an occult RCC.<sup>3</sup> We report a case of RCC with big toe metastasis revealed before the primary tumor has become apparent.

### Case report

A 72-year-old male initially presented with a 2-month history of an enlarging, tender and painful right toe lesion. The symptoms began after he accidentally hurt it. He had no previous history of gout and never had similar swellings in the past.

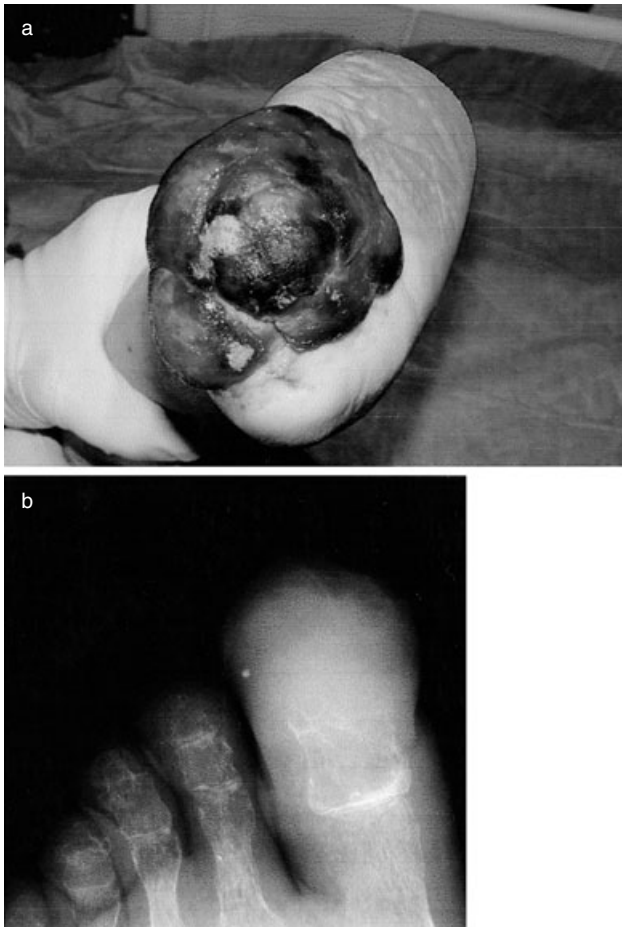
Physical examination revealed a solitary 3-cm fluctuant, violaceous subungual nodule on the right big toe displacing the shortened and discolored nail plate. The skin around the lesion was slightly red and warm with two small open wounds of the soft tissue. The first impression was that of severe osteomyelitis. After 15 days of therapy with antibiotics and antiphlogistics the wounds were enlarged while the nail was completely destroyed (Fig. 1a).

The patient underwent big toe X-ray, showing a partial destruction of the distal phalanx (Fig. 1b), and bone scintigraphy, showing a big toe uptaking radioisotope. In order to obtain a pathological diagnosis, a sample biopsy was planned. He was submitted to a routine preoperative screening, including plain X-ray that was negative for pulmonary lesions, blood analysis and cardiologic evaluation.

The sample surgical biopsy was performed and the specimen was a 2 × 1 × 1.5 cm mass with a large central wound and extensive granulation tissue. Microscopy showed groups of cells with irregular nuclear contours, prominent nucleoli and abundant vacuolated cytoplasm. Furthermore, immunohistochemical staining for epithe-

Correspondence: Sisto Perdonà MD, Via C. Battisti, 2, 80078 Pozzuoli (NA), Italy. Email: s.perdona@libero.it or rcautor@tin.it

Received 11 May 2004; accepted 1 October 2004.

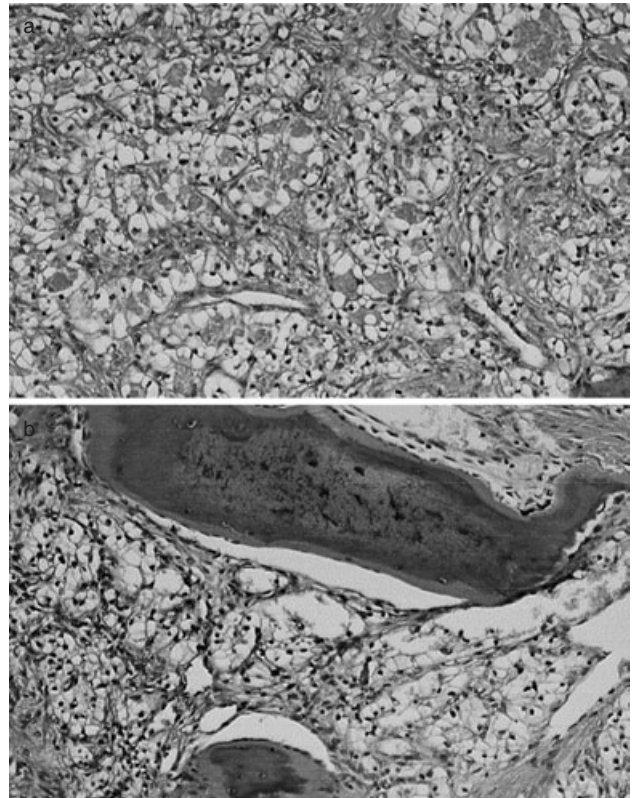


**Fig. 1** Big toe metastasis: (a) a violaceous subungual nodule on the right big toe displacing the shortened and discolored nail plate; and (b) plain X-ray shows a partial destruction of the distal phalanx.

lial membrane antigen (EMA) and cytokeratin (CK) was found to be positive. All these pathological features were suggestive of metastatic RCC.

A subsequent clinical workup was suggested. A total body computed tomography (CT) was performed, showing a 4 cm heterogeneous localized mass of the right upper renal pole with central necrosis and suspected adherence to Gerota's fascia. No metastatic sites were observed with this examination.

The patient subsequently underwent amputation of the affected toe and radical nephrectomy at the same time. The nephrectomy specimen contained a 5-cm variegated mass confined to the kidney (pT1b). The tumor was of clear cell-type with a Fuhrman grade 2 (Fig. 2a). The toe dermis and ipodermis were diffusely involved by a 5-cm neoplastic lesion. Initial erosion of cortical bone was observed. (Fig. 2b). The histological appearance was that already described. One month after



**Fig. 2** Histological appearance on specimens obtained from radical nephrectomy and toe amputation: (a) typical clear cell carcinoma; and (b) metastatic lesion with initial cortical bone infiltration.

surgery, the patient started IL2 adjuvant therapy and, after 12 months, the patient is without evidence of recurrence.

## Discussion

Renal cell carcinoma has a high propensity for early metastasis and evidence of metastases is present in about one third of patients at presentation.<sup>2</sup> Solitary metastases from a primary RCC occur in <10% of patients.<sup>4</sup> Cutaneous metastases are present in 3% to 7% of RCC cases and are the presenting symptom in 10–20%.<sup>5</sup> Osseous metastases are more common, but those to bones of the hands and feet together constitutes only about 0.1% of cases.<sup>3</sup>

Renal cell acrometastases in the hand outnumber those in the foot by a ratio of 2:1. A review of the literature reveals 41 cases (including the present case) of RCC with acrometastases, 27 of them involving the hand, 11 the foot and three involving both the hand and foot (Table 1). This fact does not follow the general rule

**Table 1** Acrometastases in patients with renal cell carcinoma; data from published literature

Author	Number of cases	Presentation	Localization	Bone metastasis	Soft tissue metastasis	Both
Troncoso <sup>6</sup>	2	Synchronous	Hand (1); Foot (1)	2	–	–
	(32)†	Not declared†	Hand (28); Foot (8); both (3)	28	2	2
Potter <sup>7</sup>	1	Metachronous	Foot	1	–	–
Abangan <sup>8</sup>	1	Metachronous	Hand	–	1	–
Kierney <sup>4</sup>	1	Metachronous	Hand	1	–	–
Adeboyega <sup>3</sup>	1	Synchronous	Hand	1	–	–
Ghert <sup>9</sup>	1	Metachronous	Hand	1	–	–
Cohen <sup>10</sup>	1	Metachronous	Hand	–	1	–
Our experience	1	Synchronous	Foot	–	–	1
Total	41	Synchronous (3) Metachronous (5)	Hand (34); Foot (11); both (3)	34	4	3

†Review data.

of supradiaphragmatic cancers metastasizing to the hands and infradiaphragmatic ones to the feet. Of the 14 RCC metastases in the foot, the bone was primarily involved in 10 cases, soft tissue alone in two cases and both soft tissue and bone in two cases (including the present case). The non-urolological and non-specific clinical and radiological presentations of these metastatic deposits may mimic other conditions, such as osteomyelitis, septic arthritis, gout, pyogenic granuloma, cutaneous horn or other osteoarthritic diseases. This fact has often resulted in erroneous diagnosis and delay in instituting the correct therapy. In addition to clinically masquerading as a benign disease, acrometastases may also present a diagnostic challenge to pathologists. The morphological appearance on microscopy is similar to that of a number of other malignant tumors (adrenocortical carcinoma, clear cell sarcoma or malignant melanoma, for example). Therefore, immunohistochemical studies should be performed to define the histogenesis of the tumor. In our experience, EMA and CK staining on the sample clarify the diagnosis.

Generally, skin metastases are metachronous from 2 months to 23 years following nephrectomy (mean, 47 months) and the longer the disease-free interval between nephrectomy and metastasis, the better prognosis.<sup>5</sup> In the present case, the diagnosis of RCC was made by histopathology after a sample excision of the only metastatic lesion to the foot with a similar size of the primary tumor. Thus, the primary RCC was discovered only after the metastatic lesion and was of low stage and grade (pT1bG2). Unfortunately, the prognosis in the present case is unpredictable due to the scarcity of data from the published literature. This kind of disease presentation has been previously reported in only two patients. In both cases, the metastasis was in the distal phalanges of the hands.

Acrometastases are often associated with widespread metastases in other areas and thus a poor prognosis. Treatment is often palliative and relief of pain is often the therapeutic goal. However, the prognosis for RCC with a solitary metastasis treated by surgical removal is far superior to that of RCC presenting with widespread metastases.<sup>4</sup>

We believe that the best treatment for a single metastasis is always surgical excision, regardless of the lesion being synchronous or metachronous. The biological behavior of metastatic RCC is unpredictable and only early diagnosis and treatment may favorably affect patient survival. In conclusion, metastatic RCC should be included in the differential diagnosis of all enlarging cutaneous nodule, wherever they occur. This is the best way to obtain an early diagnosis, choose the best treatment option and obtain a better outcome.

## References

- 1 Newmark JR, Newmark GM, Epstein JL, Marshall FF. Solitary late recurrence of renal cell carcinoma. *Urology* 1994; **43**: 725–8.
- 2 Lightfoot N, Conlon M, Kreiger N *et al*. Impact of noninvasive imaging on increased incidental detection of renal cell carcinoma. *Eur. Urol.* 2000; **37**: 521–7.
- 3 Adeboyega PA, Adesokan A, Viegas SF. Acrometastasis in renal cell carcinoma. *South. Med. J.* 1999; **92**: 1009–1012.
- 4 Kierney PC, van Heerden JA, Segura JW, Weaver AL. Surgeon's role in the management of solitary renal cell carcinoma metastases occurring subsequent to initial curative nephrectomy: an institutional review. *Ann. Surg. Oncol.* 1994; **1**: 345–52.
- 5 Lumpkin LR, Tscher JA. Renal cell carcinoma metastatic to the skin. *Cutis* 1984; **34**: 143–4.

- 6 Troncoso A, Ro JY, Grignon DJ *et al.* Renal cell carcinoma with acrometastasis: report of two cases and review of the literature. *Mod. Pathol.* 1991; **4**: 66–9.
- 7 Potter GK, Strauss H, Potter RC. Delayed appearance of metastatic renal cell carcinoma subcutaneously left fifth toe after ipsilateral nephrectomy. *J. Foot Surg.* 1991; **30**: 147–50.
- 8 Abangan DL, Solomon D, Kauffman CL. Suspicious violaceous subungual nodule. *Arch. Dermatol.* 1994; **130**: 913–18.
- 9 Ghert MA, Harrelson JM, Scully SP. Solitary renal cell carcinoma metastasis to the hand: the need for wide excision or amputation. *J. Hand Surg.* 2001; **26**: 156–60.
- 10 Cohen PR. Metastatic tumor to the nail unit: subungual metastases. *Dermatol. Surg.* 2001; **27**: 280–93.